



**VETERINARY INVERTEBRATE
SOCIETY JOURNAL**

ISSUE 1 | WINTER | 2017

CONTENTS

From the Editor	Page 1
Meet the Steering Committee	Page 2
Update from the Steering Committee	Page 4
Position Statement: Decapod Euthanasia	Page 5
Notes of Locomotion Disease in Theraphosidae Spiders Steve Trim	Page 6
Recent News	Page 6
Case Report - Histopathology of Therasposid Spider Emma Lambert	Page 7
Veterinary Input into Invertebrate Conservation Benjamin Kennedy	Page 11
Review of Fixatives for Invertebrates Benjamin Kennedy	Page 12
Horseshoe Crab Hemolymph Uses in Biomedical Research Victoria Isler	Page 13

From the Editor

Welcome to the Journal of the Veterinary Invertebrate Society! This publication has been through the process of metamorphosis and now has emerged from it's pupae to bring you the latest from invertebrate medicine. I'm very excited and happy to be now continuing what was once a very helpful and insightful publication in days gone by. We have an interesting theraphosid heavy issue with some not often seen and very informative invertebrate histology.



The Veterinary Invertebrate Society celebrates its 25th year. It is stronger than ever, welcoming vets and academics from across the world and pushing the boundaries of what we can do for our creepy and crawly neighbours.

This publication aims to be a gathering point for vets and academics, so that we can share and discuss current and upcoming research into invertebrate medicine, welfare and conservation. It

will currently involve only minor peer review but we may well consider a more robust peer review process in the future.

We welcome case reports involving invertebrates seen in practice, as we can all learn and develop our knowledge of invertebrate species further. We are also on the look out for reviews and pilot research for those that may wish to present such data to their peers.

Veterinary Invertebrate Society Steering Committee

President/Chair	John Cooper	ngagi2@gmail.com
Secretary	Sarah Pellett	sarah_pellett@hotmail.com
Treasurer	Martin Cooke	martin@ocatra.com
Webpage/Academic Liaison	Carol Trim	carol.trim@canterbury.ac.uk
Social Media/ Industry Liaison	Steve Trim	s.trim@venomtech.co.uk
Membership Secretary/ Nurse Liaison	Emily Draper	emilydraper@icloud.com
Meetings Co-ordinator	Chris Palgrave	c.palgrave@surrey.ac.uk
Zoo Liaison	Marie Kubiak	kubiakvet@gmail.com
Student Liaison	Tom Bunn	tbunn2@rvc.ac.uk
Committee Member	David Williams	dlw33@cam.ac.uk
Newsletter and Communications	Benjamin Kennedy	bkennedy2@rvc.ac.uk

Cover Image Credit: Psychonauts; Wikimedia
Toe of a Acicularia Species Theraphosid

End page Credit: JJ Harrison. (jjharrison89@facebook.com)
Clynotis severus, Female

Meet the Steering Committee

President

Professor John E. Cooper, DTVM, FRCPath, FRSB, CBiol, FRCVS
John started life as a keen field naturalist and pathologist with a focus on wildlife and exotic species and tropical diseases. He is part of a team with his wife, Margaret Cooper, a non-practising solicitor with special interests in animal and conservation law. The Coopers have spent twenty years doing work overseas, especially in Africa.



Secretary

Sarah Pellett BSc(Hons) MA VetMB CertAVP (ZM) DZooMed (Reptilian) MRCVS

Sarah works at Animates Veterinary Clinic Ltd, in Thurlby, Lincolnshire, seeing a wide range of first opinion and referral exotic animal cases. She is also a veterinary adviser on invertebrate health for the BIAZA Terrestrial Invertebrate Working Group.



Treasurer

Martin Cooke MA, Vet MD, MRCVS Veterinary Medicine, MSc
Martin is Head of Corporate Engagement at World Animal Protection, an animal welfare NGO, where he leads on corporate partnerships, mainly with global food companies, to influence improved animal welfare. He was once Editor of the Veterinary Invertebrate Society Newsletter.



Webpage / Academic Liaison

Dr Carol M. Trim PhD, MSc., BSc (Hons), MRSB, FHEA
Carol is a senior lecturer in Biology at Canterbury Christ Church University. She undertakes research into cancer biology utilising venom from theraphosids, scorpions and snakes as well as investigating best husbandry practice for invertebrates.




Social Media / Industry Liaison

Steve Trim, BSc (Hons), CBiol MRSB
Steve is the founder and managing director of Venomtech Ltd which has won awards for their outstanding animal husbandry of their invertebrates. Venomtech collaborate on a number of research projects with Canterbury Christ Church to understand more about invertebrate biology and behaviour.



Membership Secretary and Nursing Liaison

Emily Draper RVN Cert VNES MBVNA
Emily has dedicated her career to the nursing of exotic species and is currently head nurse of Orchid Veterinary Surrey in Essex. She has a particular interest in tarantulas, and is currently involved in a study on Dyskinesia Syndrome.



Meetings Co-ordinator

Dr Chris Palgrave BSc(Hons) BVM&S PhD FHEA FRCPath MRCVS
Chris is the Veterinary Pathology Centre Deputy Director & Lead Pathologist of the University of Surrey Pathology Service. He is a committee member of the BBVA (British Bee Veterinary Association) and beyond his current interests, is also interested in developing clinical pathology use in invertebrates.



Zoo Liaison

Marie Kubiak BVSc CertAVP(ZM) DZooMed MRCVS
Marie is the veterinary surgeon at West Midland Safari Park and is responsible for care of all the animals from the leaf cutter ant up to the elephant! She acts as one of the veterinary advisors for the BIAZA terrestrial invertebrate working group. Outside of work she keeps and breeds a small collection of phasmids and millipedes.



Student Liaison

Thomas Bunn, BSc (Hons)
Tom is a final year veterinary student at the Royal Veterinary College interested in the husbandry and medicine of all species. He is keen to encourage more students to gain an awareness for invertebrate medicine.



Committee Member

David Williams MA VetMB PhD CertVOphthal CertWEL FHEA FRCVS
David has written and spoken on exotic ophthalmology internationally, which naturally extends into invertebrates and their health. The complexity and sophistication of invertebrate eyes illustrates how we should consider these animals with more care than we sometimes do.



Newsletter and Communications

Benjamin Kennedy BSc. MSc BVetMed MRCVS MRES
Benjamin's ultimate goal is to create an environment where there is expertise and enthusiasm for the veterinary care of invertebrates. He feels in particular that invertebrates are worthy of the same level of care and respect that is dedicated to other more conventional domestic species.



The Committee are happy to provide advice. Please contact us through the communication channels shown below.



vetinvertsoc@gmail.com



<http://www.facebook.com/vetinvertsoc>



<http://www.linkedin.com/groups8586084>



[@vetinvertesoc](https://twitter.com/vetinvertesoc)

Update from the Steering Committee

Successful Website and Social Media Presence

The website that was run by the old steering committee has now been shut down and replaced with a new website currently run by Carol Trim. The society now has an active social media presence which acts as a contact point for members of the public as well as a source of veterinary news.

Position Statements

The committee is in the process of developing some position statements regarding euthanasia protocols and into invertebrate conservation. The position on decapod euthanasia for food preparation is now available in this issue for comment from the membership.

Associations with Other Organisations

We have developed an association with the Royal Entomological Society and the Amateur Entomological Society. A number of our members engaged with the Royal Entomological Society earlier on in the year with some very positive results.

Upcoming Meetings

We are currently planning two meetings provisionally on the **19th May 2018** and in October 2018. The first meeting will be with the British Bee Veterinary Association. The second meeting will be a solely VIS meeting. More details will be coming in the new year.

Veterinary Recommendation/Accreditation Scheme

It has become clear that finding a vet with an invertebrate interest can be very challenging for keepers and for first opinion vets. After consultation with the RCVS and within the VIS steering committee, the society has began the process of developing a vet recommendation scheme with the aim

of directing invertebrate keepers to vets that have expertise and experience in invertebrate care.

This scheme will endeavour to bridge the gap that can develop between invertebrate keepers and the veterinary profession. It will be run in a similar manner to the scheme run by the Rabbit Welfare Association. In a nutshell, it will involve a questionnaire and a discussion with any vet that may wish to be involved and be recommended.

Any opinion, perspectives or feedback from the membership of the society would be greatly appreciated.

New Ventures and Projects

The Steering Committee includes several academics and vets that are involved in academia. This has allowed the VIS to become involved in direct research into invertebrate health and medicine. Current projects include:

- Developing reference images of normal and pathological histology in various invertebrate species.
- Assessing safety and efficacy doses in various feed invertebrates with plans to extend this to theraphosid spiders and other important species.

- Establishing efficacy of different euthanasia protocols.
- Developing treatments and expertise for diseases of concern in specific invertebrate species (e.g. Dyskinesia Syndrome in theraphosid spiders)

If any of these projects are of interest to members of the society, then do get in contact with us so we can collaborate.

Membership Fees

In the new year, the society will be introducing a £20 fee for membership. Students will still have free membership. Though this society has run for many years with no membership fee, we have now become larger and are undertaking regular meetings and publications (like this one). A modest fee is required to maintain these activities. We will always endeavour for any membership fee to be modest. We always welcome the perspective of our members on membership fees so do get in touch.

The next meeting is provisionally planned for:
19th May 2018



Members of our Steering Committee donning a non-chitinous exoskeleton.

Notes on Locomotion Diseases in Theraphosidae Spiders

Steve Trim BSc (Hons) CBiol MRSB

There are many people who keep Theraphosidae spiders as pets and exhibit animals (also commonly called tarantulas). Amongst professionals and hobbyists alike; unusual, jerking and poorly coordinated limb movements have been noticed and appear to relate to a degeneration in normal behaviours such as feeding, burrowing and ecdysis. This frequently progresses to death with unknown aetiology. For many years there has been great debate as for potential causes and even if it is a disease at all. To date very little research has been performed.

In October 2014 a meeting of the VIS and BIAZA TIWG confirmed the use of Dyskinesia Syndrome (shortened to DKS) as the official description for such ataxic movements. The use of the word syndrome signifies the lack of knowledge as all we know about the condition is a collection of clinical signs. In order to understand this syndrome, the VIS are keen to collate any case reports of clinical signs similar to Dyskinesia Syndrome for a review currently underway. The signs associated with DKS are, hunched posture, ataxic movements, anorexia, loss of righting reflex, and death. In vertebrates these symptoms are associated with neurological dysfunction and this is likely in theraphosidae too, however causes of such dysfunction are diverse and include, dehydration, infection, intoxication and neuronal injury. Many of these could indeed be causative agents for DKS and it is very likely that further investigation will reveal slightly different pathologies arising from different causes.

A defining case of DKS in 2011 was observed in an adult female Trinidad Chevron Spider *Psalmopoeus cambridgei* being housed at Venomtech. In typical form the spider was found unable to right itself and making jerky movements when touched. When spiders are in this state we have found that liquids can be given orally with a pipette. Initially critical care

formula (Vetark) was prepared as for reptiles and given orally by pipette daily for 11 days, however no improvement was noticed. It was at this point where a mixed salt solution was prepared to replace electrolytes that are crucial in neuronal signalling and kept at 0.9% w/v. This solution was given orally daily as previously, however after a further ten days the patient was able to write itself and climb the enclosure walls. Spider was tong fed a locust, 26 days post diagnosis and was feeding normally after 35 days. After which the spider behaved normally for the next five years, after which it slowed down and died. There were no unusual findings on gross necropsy, however histology was not available.

Since then we have used the salt solution, now called Spider Saver™ in two other cases and it is offered to anyone with such cases to in return for collating case notes to add to the knowledge of Dyskinesia syndrome and to hopefully work towards a robust treatment.

The VIS aim to produce a review paper of DKS cases in 2018 and ask if anyone has any cases that could assist in this research to contact us.

Contact emails for Steve and Emily:
s.trim@venomtech.co.uk
emilydraper@icloud.com



P. Cambridgei

Credit: Micha L. Rieser, Attribution,
<https://commons.wikimedia.org/w/index.php?curid=6484085>

Recent News

Tragic Death of Invertebrate conservationist, Tony Whitten

Tony Whitten founded the IUCN (International Union for Conservation of Nature) Species Survival Commission Specialist Group on Cave Invertebrates. Several of the VIS steering committee met and discussed collaborations with him before his death. We remember his passion and enthusiasm for invertebrate conservation well. The invertebrate world is small, so it is especially sad when one of our own is lost to us. The thoughts of the society are with Tony's family and colleagues.

Recent Rediscovery of the Bee-Mimicking Moth in Malaysia

There has been a very heartening re-discovery of a species of bee mimicking clear wing moth *Heterosphecia tawonoides* in a similar manner to the well known *Dryococelus Australis* stick insect. These stories of invertebrates surviving against the odds in the face of habitat destruction are always encouraging for those of us that work towards ensuring invertebrate conservation.

DOI link of the primary paper:
<http://journals.sagepub.com/doi/full/10.1177/1940082917739774>

75% Loss of Insect Biomass over Past 27 years in Protected Areas in Europe

In less optimistic news, a recent study found a profound loss of flying insect biomass in protected areas in Germany and the United Kingdom. This loss was found to be independent of climate change and habitat type. Agricultural intensification is discussed as a potential source. Flying insects not only serve as food sources for vertebrate species but also as key pollinators for any of our native species. This research illustrates the need for more attention and care for invertebrate conservation.

DOI link of the primary paper:
<http://journals.plos.org/plosone/article?id=10.1371/journal.pone.0185809>

Position Statement on Recommendations for Euthanasia of Decapods for Food

Decapods (i.e. Lobster and Crab) represent a commonly prepared food species. This species set is of great importance to the culinary industry. It has been established that crustaceans have a significant level of pain perception with the cognitive ability to remember and avoid noxious stimuli (Barr et al., 2008; Elwood, 2012).

Though pain perception of decapods may well be of a different nature to mammalian species; it is still important to reduce the level of suffering of these animals when being prepared for food (Yue, 2008).

The Veterinary Invertebrate Society advocates for decapods to be stunned and euthanised before cooking as per recommendations by the RSPCA Australia as so to reduce the suffering during throughput preparation to an absolute minimum.

These can be found at: http://kb.rspca.org.au/What-is-the-most-humane-way-to-kill-crustaceans-for-human-consumption_625.html

These recommendations include stunning via specialised electrical stunner, chilling in an ice slurry (where appropriate to species) or chilling within air (where appropriate to species). In regards to euthanasia, efficient mechanical killing methods which specifically targets nervous ganglion (I.E. spiking and splitting) are acceptable.

The Veterinary Invertebrate Society does not condone or recommend live

mechanical killing or preparation without stunning.

References

- Barr, S., Laming, P.R., Dick, J.T.A., Elwood, R.W., 2008. Nociception or pain in a decapod crustacean? *Anim. Behav.* 75, 745–751.
<https://doi.org/10.1016/j.anbehav.2007.07.004>
- Elwood, R., 2012. Evidence for pain in decapod crustaceans. *Anim. Welf.* 21, 23–27.
<https://doi.org/10.7120/096272812X13353700593365>
- Yue, S., 2008. The welfare of crustaceans at slaughter. *Welf. Crustac. Slaught.*

We welcome any comment or opinion in this position statement as it will represent the view of the Society.
Please contact one of the Steering committee or the Society email address: vetinvertesoc@gmail.com



Case Report - Histopathology of Avicularia Species Theraphosid following Sudden Death

Emma Lambert BSc LIBMS

This case report covers the sudden death of a avicularia species theraphosid spider and the histopathology undertaken

General Husbandry

The tarantula was a sub-adult male Avicularia species sold as juvenile “Avicularia Common Pink Toe”. He was confirmed as male by examination of a recent moult produced during ecdysis. He was likely a penultimate male by his size. The temperature and humidity within the tank remained stable at around 24°C and 70% humidity respectively prior to onset of clinical signs, though these measurements could potentially be unreliable.

History and Presentation

Initially the tarantula recovered well following ecdysis and was mobile. Anorexia was noted one month following his moult, which was in January. The tarantula was observed

to have apparent coprophagia twice when anorexic. Nematodes were not found when fecal samples were examined microscopically and appeared to be acellular.

After three months of anorexia the tarantula began to display paralysis of a rear leg which appeared to lie lifelessly. Further examination was unremarkable other than lethargy. Two days following onset of paralysis, the tarantula was found dead in a classic ‘death curl’ posture. The tarantula had been dead for at least 8 hours so the decision was made to fix the body in order to determine cause of death through histology. He was fixed in formalin 10% neutral buffered solution around 48 hours post death.

Details of Fixation and Preparation of Slides

He was bisected longitudinally prior to immersion into formalin. The defective leg was removed, bisected longitudinally and placed into a

separate container. The fangs were removed from the base as they were exceptionally tough and likely to make microtomy difficult, reducing overall section quality.

After overnight fixation representative tissue blocks were taken, these included; the defective leg, a ‘normal’ leg, a pedipalp, the cephalothorax and opisthosoma. These were processed from formalin into paraffin wax overnight by conventional histology methods. Sections were taken on a rotary microtome, cut at 3 microns thick onto non coated glass slides and stained with haematoxylin and eosin.

Summarised on the next pages are representative images of the slides produced. These will be useful for anyone that may want a comparison when doing theraphosid histology.

Emma works as a biomedical scientist within a hospital. She keeps several invertebrates and is a member of the British Tarantula Society.
Email: emmaroseh@ntlworld.com



External appearance of Avicularia animal on right. Recent moult present on left.


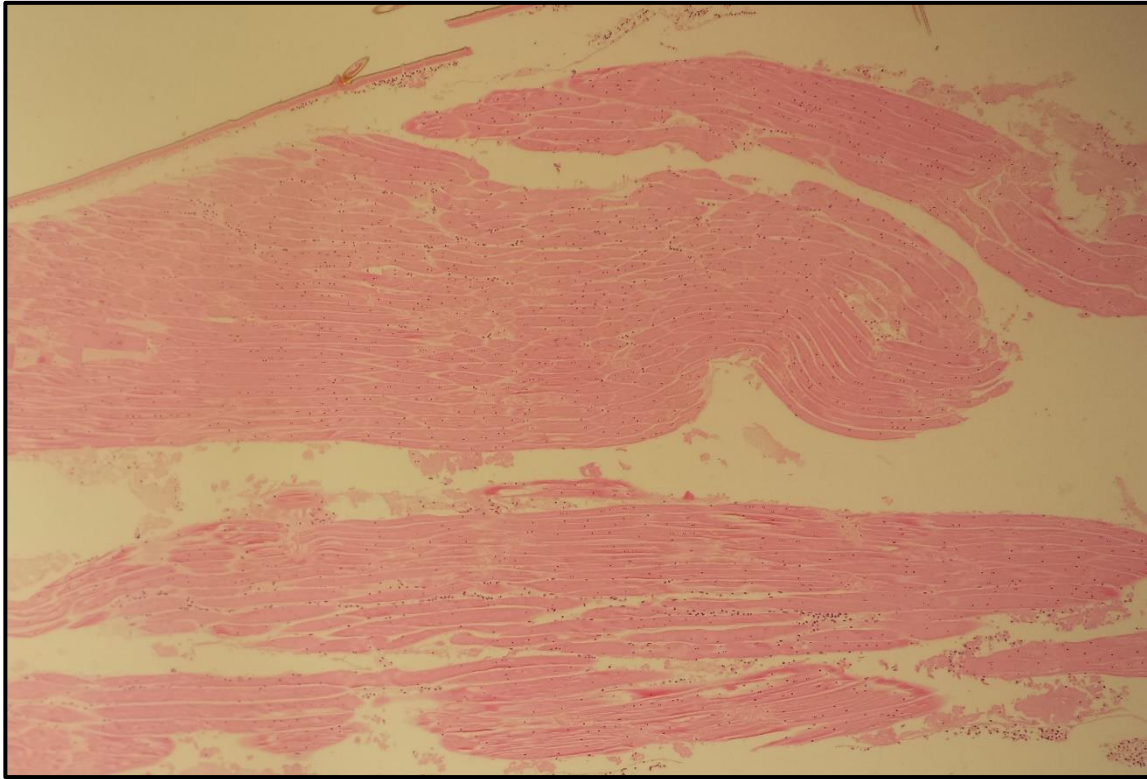
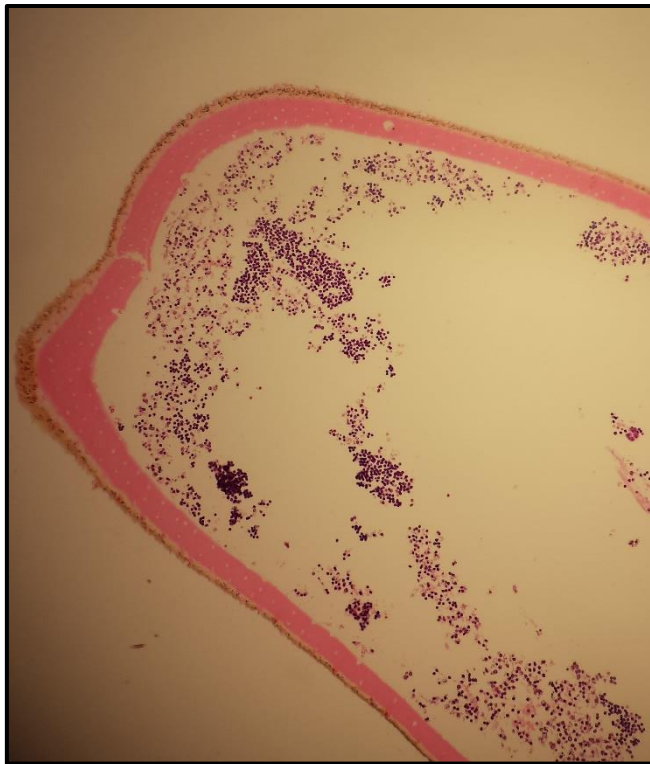


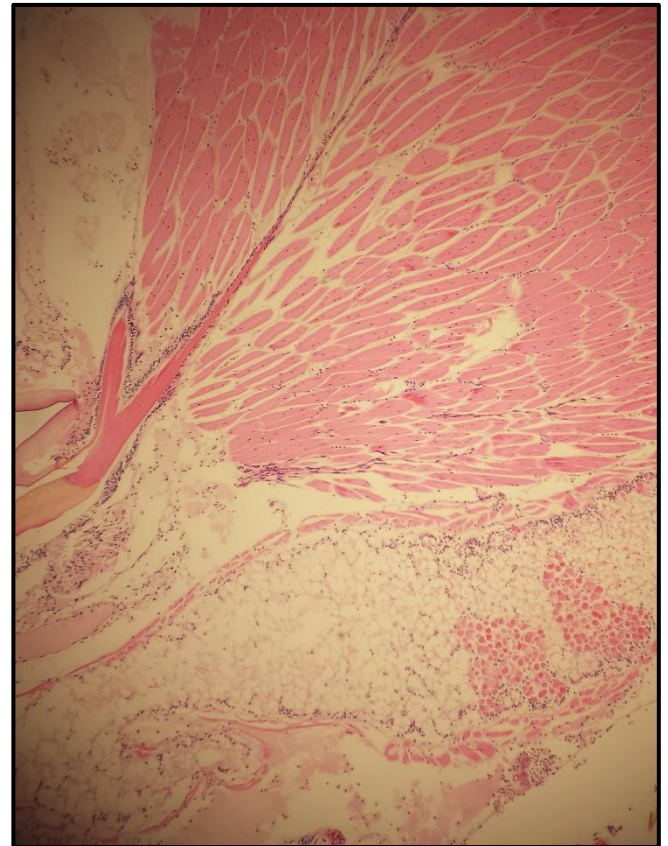
Image of the tehraphosid spider while alive



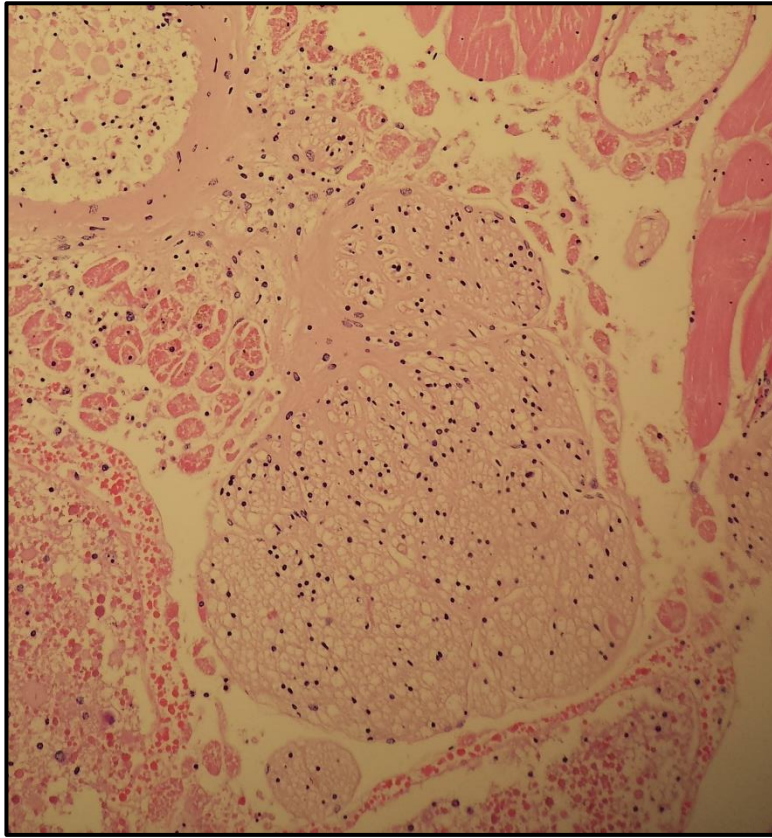
Muscle tissue from defective leg



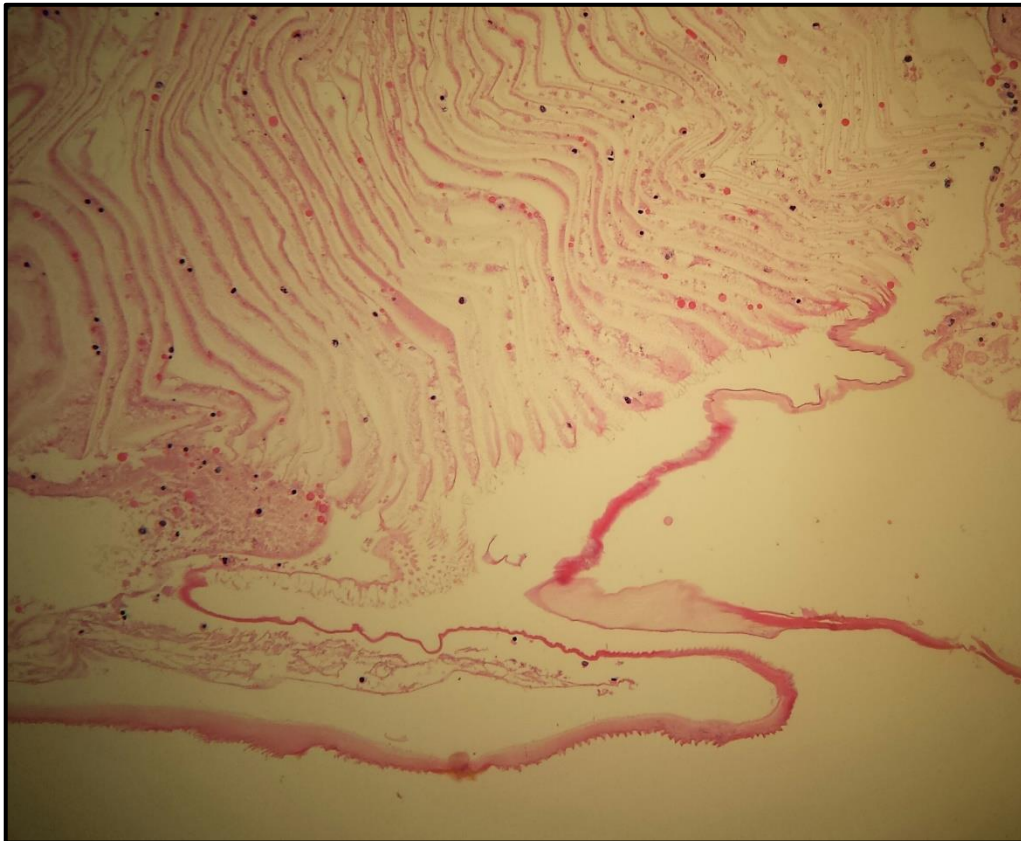
Transverse section from distal tarsus of damaged leg.



Section from Chelicera near fang base



Cephalothorax Ganglion



Section of Book lung

The Potential of Veterinary Input into Invertebrate Conservation

Benjamin Kennedy BSc MSc BVetMed MRCVS

Invertebrate conservation is an oft passed over subject but is increasingly gaining more attention and more traction. In the same way that the nature of invertebrate collections can allow conservation and breeding programs to be very successful, these same features can also present some key challenges (Pearce-Kelly et al., 1998). Invertebrates can often be kept in large numbers, confined spaces and depending on the species, humid conditions. Sometimes dozens of species can be kept in a single room and this can allow very efficient conservation to occur, but in the worst-case scenario, disease can spread across multiple species quickly. This can result in significant mortality, and in the extreme, even extinction (Cunningham and Daszak, 1998).

Indeed, though the humid and hot environment can often be a requirement of good husbandry, it can also create the perfect breeding ground for bacterial, fungal and parasitic disease.

The understanding of invertebrate biology is commonly based on old studies (sometimes from the turn of the 20th Century), which though very helpful, can be limited by the tools available at that time. Even now, science continues to make new discoveries into how disease and pathology can influence invertebrate biology as we begin to apply modern clinical tools.

Clinical pathology in the form of histology, culture and PCR aren't often applied to invertebrate species in the same way that the more personable vertebrates are. These tools have the potential to increase our capacity to captive-breed these animals, improve overall welfare and ultimately to increase their exhibition potential (Cunningham, 1997). From a pure business point of view, if an animal can have an increased lifespan when exhibited, then zoological collections will become less reliant on wild-caught specimens and on their own captive

breeding programs. This in turn would allow these organisations to pursue more conservation work.

Some of the stories within invertebrate conservation show us some key lessons in respect to the role that veterinary medicine may play in conservation. One of these would be the story of the phasmid species *Dryococelus australis*, also known as the 'Lord Howe stick insect' (Honan, 2008; Priddel et al., 2003). This species was at one time reduced to two individuals (due to predation by introduced rodents) but was brought back from those two individuals to having successful breeding programs not only in Sydney but also across the world (including our own conservation programme at Bristol Zoo). Part of this story that is always quite telling to us as veterinarians is that when this species was confined to such a small number; there was significant disease in which one of the individuals needed veterinary intervention. This illustrates how veterinary attention and consideration can have a profound effect on the ability of the species to survive in the face of increasing habitat destruction and conservation challenges.

Another more bittersweet story within invertebrate conservation is that of one of the *Partula* snail species. There has been a successful and fruitful *Partula* snail breeding program held at the Zoological Society of London for many years. However, this species set has also had some set-backs, as in 1996 a

microsporidian parasite was implicated in the extinction of one of the *Partula* snail species (Cunningham and Daszak, 1998). This represents a rare example of a disease process being responsible for the extinction of any species.

Perhaps with more knowledge and expertise in invertebrate disease and the practical implementation of this to their care we could prevent another invertebrate extinction such as this in the future.

References

- Cunningham, A.A., 1997. Invertebrate pathology: a developing and essential science for invertebrate conservation. *Mem. Mus. Vic.* 56, 647–648. <https://doi.org/10.24199/j.mmv.1997.56.64>
- Cunningham, A.A., Daszak, P., 1998. Extinction of a species of land snail due to infection with a microsporidian parasite. *Conserv. Biol.* 12, 1139–1141.
- Honan, P., 2008. Notes on the biology, captive management and conservation status of the Lord Howe Island Stick Insect (*Dryococelus australis*) (Phasmatodea). *J. Insect Conserv.* 12, 399–413. <https://doi.org/10.1007/s10841-008-9162-5>
- Pearce-Kelly, P., Jones, R., Clarke, D., Walker, C., Atkin, P., Cunningham, A.A., 1998. The captive rearing of threatened Orthoptera: a comparison of the conservation potential and practical considerations of two species' breeding programmes at the Zoological Society of London. *J. Insect Conserv.* 2, 201–210.
- Priddel, D., Carlile, N., Humphrey, M., Fellenberg, S., Hiscox, D., 2003. Rediscovery of the 'extinct' Lord Howe Island stick-insect (*Dryococelus australis* (Montrouzier))(Phasmatodea) and recommendations for its conservation. *Biodivers.*



Dryococelus Australis

Credit: Granitethighs; Wikimedia

Recommendations for Fixing Techniques for Terrestrial Invertebrate Histopathology

Benjamin Kennedy BSc MSc BVetMed MRCVS

Histology can be a valuable tool in determining cause of disease in veterinary medicine where post mortem examination or gross examination alone can be limited. There has been some work establishing some reference histology in various invertebrate species, but this is relatively small compared to vertebrates (Cunningham, 1997). There may well be diseases and pathology present in invertebrate collections that we are unaware of because histopathology isn't commonly applied. Clinical pathology can guide future procedures and medicine thus decreasing levels of disease and pathology in collections. This in turn could result in animals with a longer and healthier life span, and in more fruitful captive breeding programs.

Euthanasia and fixation guidelines

Invertebrates should be fixed as quickly as possible as they are prone to desiccation and autolysis. Any invertebrates that are found dead should be fixed and/or sampled immediately if good histology is to be attained. In the Author's experience fixation within 12 hours of death is ideal. The level of autolysis will be variable depending on the humidity and temperature of the vivarium. Even if an animal has been deceased for more than 24 hours, viable histology can still be attained (Berzins et al., 2011).

Having a set protocol and plan in place for specific exhibits/animals (those of high conservational and economic value or those exhibits that are having significant problems with disease) can reduce the time needed to decide to fix and in turn improve the quality of the information gained from sampling.

Ideally, if an invertebrate has significant disease with clear lesions (and treatment has either been attempted or isn't possible), then euthanasia and immediate fixation will result in better and more viable histology. Euthanasia via freezing is not conducive to attaining good histology. Barbiturates

or potassium chloride under general anaesthesia work well as euthanasia methods (Bennie et al., 2012; Cooper, 2011).

When fixing an animal post-euthanasia, ensure that volume of fixative is at least 8-12 times the volume of the animal. Making an incision with a needle or scalpel blade through the dorsal or ventral midline of the exoskeleton will result in faster uptake of the fixative. In addition to this, separating the opisthosoma and prosoma (abdomen and thorax) will further improve fixation. Alternatively, if a member of the team is confident with pericardial injections, then injecting fixative directly into the pericardial sac following euthanasia can be another way of ensuring rapid fixation.

In a nutshell, the more immediate the fixation following death, the better the histology and the better the conclusions that can be gained.

Fixation mediums

There are multiple different choices of fixation mediums available. The following examples mentioned here are: 70% isopropanol, 10% formalin and Kahle's fixative. Exchanging water components with saline or sea water can improve quality of histology in crustaceans and other saltwater based invertebrates. (Berzins et al., 2011; Donald V. Lightner, 2017; Howard et al., 2004)

70% isopropanol fixation can harden tissue and so it can be more time intensive and challenging to generate slides from invertebrates as the exoskeleton can become difficult to manipulate and this can result in a loss of detail on histology. Other diagnostic tests can be performed on isopropanol fixed samples beyond histology. Isopropanol is less toxic than alternatives but is very flammable so it should still be handled and stored carefully. As isopropanol is not as caustic or toxic as formalin there are less concerns about its use.

Formalin fixation is a well-established fixation medium and will be available from the majority of veterinary surgeries. The exoskeleton is still prone to harden but less so than isopropanol. Histology tends to be better with formalin but further diagnostics are limited (i.e. genetic and biochemical testing). Formalin is toxic and thus care should be taken when handling and disposing of it. This can make it a difficult choice for zoological collections due to concerns with its use by non-clinical personnel.

Kahle's fixative is a mixture of fixatives with acetic acid. The acetic acid works well to soften the chitinous exoskeleton of invertebrates. It isn't appropriate for long term storage. Fixation in Kahle's for 24-48 hours (depending on cuticle thickness) is usually sufficient before transferring to another fixative. The Kahle's recipe could be made up by any good pathology lab should anyone wish to have this on hand.

References

- Bennie, N.A.C., Loaring, C.D., Bennie, M.M.G., Trim, S.A., 2012. An effective method for terrestrial arthropod euthanasia. *J. Exp. Biol.* 215, 4237–4241. <https://doi.org/10.1242/jeb.074997>
- Berzins, I.K., Smolowitz, R.M., Lewbart, G.A., 2011. Diagnostic Techniques and Sample Handling, in: *Invertebrate Medicine*. Wiley-Blackwell, pp. 389–400. <https://doi.org/10.1002/9780470960806.ch22>
- Cooper, J.E., 2011. Anesthesia, analgesia, and euthanasia of invertebrates. *ILAR J.* 52, 196–204.
- Cunningham, A.A., 1997. Invertebrate pathology: a developing and essential science for invertebrate conservation. *Mem. Mus. Vic.* 56, 647–648. <https://doi.org/10.24199/j.mmv.1997.56.64Donal>
- Donald V. Lightner, 2017. Chapter 2.2.0 General information on diseases of crustaceans, in: *Manual of Diagnostic Tests for Aquatic Animals*.
- Howard, D.W., Health, C. for C.E., Laboratory, B.R. (U.S.) C.O., 2004. Histological techniques for marine bivalve mollusks and crustaceans, NOAA technical memorandum NOS NCCOS. NOAA, National Ocean Service, National Centers for Coastal Ocean Service, Center for Coastal Environmental Health and Biomolecular Research, Cooperative Oxford Laboratory.

Horseshoe Crab Hemolymph uses in Biomedical Research

Victoria Isler

The horseshoe crab present in the Atlantic ocean, *Limulus polyphemus*, is commercially farmed and bled for use in biomedical research. The hemolymph is collected from horseshoe crabs via the arthroal membrane and up to 200-400 mL of blood can be collected from larger horseshoe crabs (Armstrong & Conrad, 2008). It is commonly used in immunology studies due to the ability of their granular amoebocytes to bind bacterial endotoxins (Armstrong & Conrad, 2008). The amoebocytes are the only cell type present in their blood and contain all the factors and proteins necessary to clot the blood in the presence of microbes and the lysate that is able to detect gram-negative bacteria (Mürer et al., 1975). Within the granules of the amoebocytes is coagulin that is released to aid with aggregation of the amoebocytes and protein in blood clotting (John et al., 2010). The granules are released in the presence of microbes.

This process is specifically sensitive to gram-negative bacteria. The lysate from the *Limulus* amoebocyte binds to the endotoxin lipopolysaccharide (LPS) that is present in the cell membrane of gram-negative bacteria (John et al., 2010). The LAL test has been created that uses the *Limulus* amoebocyte lysate (LAL) to test for the presence and quantity of bacterial endotoxins present in a sample (John et al., 2010). These tests are widely used in testing for contamination of medical devices,

vaccines, and a variety of patient samples. In 2017, a study was done using the LAL assay to test for the presence of gram-negative bacteria in oral samples of human patients undergoing chemotherapy and radiation (Matthews, 2017). The assay allowed for testing of disruption of the normal oral flora of the mouth due to cancer therapy. The LAL assay allows for sensitive testing of gram-negative bacteria, even in low numbers that would normally be undetected by previous assays used such as the USP rabbit pyrogen test, used commonly before the use of *Limulus* hemolymph (John et al., 2010). The LAL assay is up to 300 times more sensitive than the USP rabbit pyrogen test (John et al., 2010).

Due to the sensitivity of the hemolymph of horseshoe crabs and the large quantity of blood that can be easily collected, horseshoe crabs are being used for blood collections in high numbers. There is concern for survival of the horseshoe crabs after they have been bled because they take longer to return to baseline levels of amoebocytes (Linesch, 2017). However, there was low mortality in the horseshoe crabs that were monitored after release. Therefore, their use in biomedical research allows for sensitive detection of bacterial endotoxins and may not affect the ability for the horseshoe crabs to survive.

References

- Armstrong, P., & Conrad, M. (2008). Blood collection from the American Horseshoe Crab, *Limulus polyphemus*. *Journal of Visualized Experiments*, (20). doi:10.3791/958
- John, B. A., Jalal, K., Kamaruzzam, Y., & Zaleha, K. (2010). Mechanism in the Clot Formation of Horseshoe Crab Blood during Bacterial Endotoxin Invasion. *Journal of Applied Sciences*, 10(17), 1930-1936. doi:10.3923/jas.2010.1930.1936
- Linesch, K. (2017). Evaluating Best Management Practices in the South Carolina Horseshoe Crab Fishery: A Field Approach to Determine Physiological Impacts of the Biomedical Bleeding Process. *ProQuest Dissertations Publishing*. Retrieved November 30, 2017, from <https://search.proquest.com/openview/512d30d2997ea5b773247b364082b02f/1?pq-origsite=gscholar&cbl=18750&diss=y>.
- Matthews, J. S. (2017). Detection of aerobic gram-negative bacteria and bacterial endotoxins from the oral cavities of patients on cancer therapy. *University of the Witwatersrand*. Retrieved November 30, 2017, from <http://hdl.handle.net/10539/23204>
- Mürer, E. H., Levin, J., & Holme, R. (1975). Isolation and studies of the granules of the amoebocytes of *Limulus polyphemus*, the horseshoe crab. *Journal of Cellular Physiology*, 86(3), 533-542. doi:10.1002/jcp.1040860310

Victoria is a Veterinary Student at
North Carolina State University
Email: vlisler@ncsu.edu

Article Submission – The Journal of the Veterinary Invertebrate Society welcomes articles on all aspects of invertebrate health, medicine and welfare. We favour articles that involve practical application of veterinary principles to invertebrates animals and their care.

We seek clinical case reports, original research findings, review articles, meeting reviews and short communications. We intend to produce a journal of a high standard and so we may choose to reject an article that is poorly written or not up to a reasonable academic standard. Peer review will be provided as appropriate to the article submitted. This journal is an English language journal. The Harvard referencing style should be used.

Please do not hesitate to contact the editor for guidelines should you wish to submit an article. Contact: bkennedy2@rvc.ac.uk or vetinvertsoc@gmail.com

JOURNAL OF THE VETERINARY INVERTEBRATE SOCIETY
ISSUE 1 | WINTER | 2017

